



# Extreme Lateral Lumbar Interbody Fusion Surgery with a Robot-Assisted System in a Swine Model

Gurkan BERIKOL<sup>1</sup>, Abuzer GUNGOR<sup>2,8</sup>, Mehmet Berke GOZTEPE<sup>3</sup>, Baris OZONER<sup>4</sup>, Selim AYHAN<sup>5</sup>, Ebubekir AKPINAR<sup>2</sup>, Cagri CANBOLAT<sup>6</sup>, Mehmet Emin AKSOY<sup>7</sup>, Murat Sakir EKSI<sup>8</sup>

<sup>1</sup>Taksim Training and Research Hospital, Department of Neurosurgery, Istanbul, Turkey

<sup>2</sup>Istanbul Bakirkoy Prof. Dr. Mazhar Osman Psychiatric and Nervous Diseases Training and Research Hospital, Department of Neurosurgery, Istanbul, Turkey

<sup>3</sup>Akdeniz University, School of Medicine, Antalya, Turkey

<sup>4</sup>Kartal Dr. Lutfi Kirdar Training and Research Hospital, Department of Neurosurgery, Istanbul, Turkey

<sup>5</sup>Baskent University School of Medicine, Department of Neurosurgery, Ankara, Turkey

<sup>6</sup>Memorial Hizmet Hospital, Department of Neurosurgery, Istanbul, Turkey

<sup>7</sup>Acibadem Mehmet Ali Aydinlar University, Vocational School of Health Services, Department of Biomedical Device Technologies, Istanbul, Turkey

<sup>8</sup>Yeditepe University, School of Medicine, Neurosurgery Research Laboratory, Istanbul, Turkey

**Corresponding author:** Gurkan BERIKOL ✉ dr.berikol@gmail.com

## ABSTRACT

**AIM:** To evaluate the technical aspects of the Da Vinci Xi Surgical System in minimally invasive extreme lateral lumbar interbody fusion (XLIF) surgery in a swine model.

**MATERIAL and METHODS:** Endoscopic discectomy and XLIF cage insertion were performed using a robot-assisted system. The time taken and the pros and cons of each steps were recorded.

**RESULTS:** A total of 4 ports were used for the surgical access; one for the camera, two for bipolar forcepses, and one auxiliary port for modified discectomy. Punch and curette were used for discectomy. The cage was inserted through the auxiliary port. Cage position was manipulated and checked by using the C-arm fluoroscopy. The operative time was 80 minutes. No complications or cage malposition was noted throughout the procedure.

**CONCLUSION:** This study shows that the robot-assisted XLIF approach is safe and feasible, and helps to protect the neurovascular structures. Moreover, a high image quality was also obtained during the procedure.

**KEYWORDS:** Robotic surgical procedures, Spinal fusion, Discectomy, Spine

**ABBREVIATIONS:** ALIF: Anterior lumbar interbody fusion, FDA: Food and Drugs Administration, TLIF: Transforaminal lumbar interbody fusion, XLIF: Extreme lateral lumbar interbody fusion

## INTRODUCTION

Robotic surgical procedures are becoming increasingly popular with advances in technology. Minimally invasive procedures have gained considerable attention in the recent decade to overcome common complications

associated with conventional spinal procedures (17). Despite being minimally invasive, the preference for robotic surgical procedures among spinal surgeons is low compared with other specialists. The robotic systems used for spinal procedures are Mazor (Medtronic Navigation, Louisville, CO, USA), Excelsius

Gurkan BERIKOL : 0000-0001-6434-8143  
Abuzer GUNGOR : 0000-0002-2792-7610  
Mehmet Berke GOZTEPE : 0000-0002-1193-3696

Baris OZONER : 0000-0003-0534-2766  
Selim AYHAN : 0000-0003-0153-3012  
Ebubekir AKPINAR : 0000-0002-4069-0021

Cagri CANBOLAT : 0000-0003-3576-5305  
Mehmet Emin AKSOY : 0000-0003-3227-2660  
Murat Sakir EKSI : 0000-0002-3036-0061

(Globus Medical, Inc., Audubon, PA, USA), ROSA Spine Robot (Zimmer Biomet, Warsaw, IN, USA), Cirq Spinal Robot (Brainlab AG, Munich, Germany), Fusion Robotics Spinal Navigation and Robotic System (Boulder, CO, USA), and TiRobot (TINAVI Medical Technologies, Beijing, China) (1). The Da Vinci Xi Surgical System (Intuitive Surgical, Sunnyvale, CA, USA) has been approved by the Food and Drug Administration (FDA) in the United States for minimally invasive interventions (3,4,27). This system is a convenient tool in urology, ear-nose-throat, cardiothoracic surgery, and general surgery; however, many neurosurgeons remain unfamiliar with it.

Robotic surgical procedures are recommended for operations requiring effective reconstructive techniques (39), as the instruments provide flexibility and steadiness to surgeons hands and the cameras and two high-resolution lenses provide three-dimensional vision (9,56). Compared with microscopic surgery, robotic surgical procedures have advantages and disadvantages. They provide an ergonomic console to better command the robot by scaling the surgeon's movements (4). The major disadvantages are the lack of tactile feedback and relatively high costs (56). Operational ergonomics is as important as control and precision in spinal operations (43). Robotic surgical procedures improve the comfort of surgeons, shorten hospital stay, and decrease postoperative pain and morbidity (26). Other limitations, such as insufficient power to manipulate procedures while cutting bones, have delayed the progress of robot-assisted spinal surgery (56). Cadaver and animal studies have attempted to overcome these limitations (26,43,56). However, there is still a knowledge gap and further need for animal and clinical studies to better delineate the role of robotic surgical procedures in spinal surgery. Extreme lateral lumbar interbody fusion (XLIF) is an indirect and minimally invasive procedure for neural spinal decompression. To the best of our knowledge, robot-assisted discectomy and XLIF cage insertion have not been reported in the literature.

The transperitoneal or retroperitoneal approach to the lumbosacral vertebrae, transoral approach to the skull base, and craniocervical junction are considered appropriate locations for robotic surgical procedures in the field of neurosurgery (29). Swine models are appropriate for spinal surgery studies because they are similar to humans in size and tissue (43,56). In this study, we aimed to investigate the feasibility of robot-assisted discectomy and cage insertion using an extreme lateral approach to the lumbar vertebra in a swine model. We also aimed to identify the advantages and disadvantages of the robot-assisted system in this scenario.

## ■ MATERIAL and METHODS

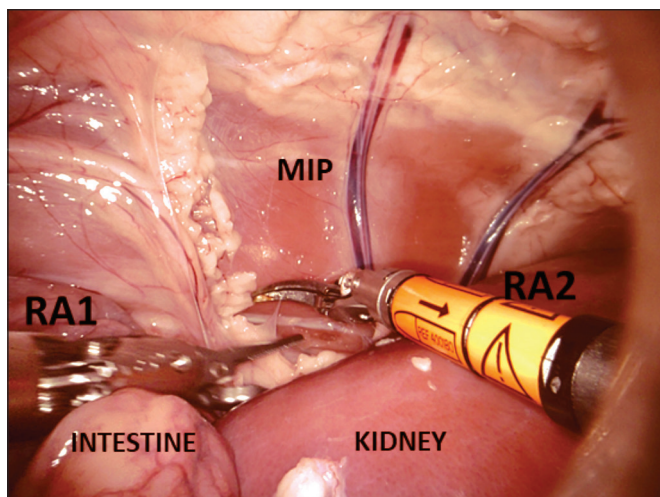
This study was conducted with approval from the Acibadem Mehmet Ali Aydınlar University Clinical Simulation and Advanced Endoscopic Robotic Surgery Training Center. A robot-assisted lateral approach was used on the lumbar spine of a 52-kg frozen swine cadaver. Surgical procedures were performed by two neurosurgeons who received robot-assisted surgery certification for the Da Vinci Xi Surgical System. The surgical procedure for the thoracic spine and surgical steps have been previously described in detail (19). The swine was

placed in the left lateral decubitus position. Four ports were used: one 12-mm port for the endoscope camera, two 8-mm ports for the robotic arms (bipolar forceps), and one 12-mm auxiliary port for discectomy and cage insertion. CO<sub>2</sub> was administered for inflation of the abdomen. An 8-mm, 0° Da Vinci Xi 3D endoscope camera was used; an 8-mm, 30° endoscope camera was also available for use if required. A curved bipolar dissector, bipolar forceps, and robotic instruments were used for dissection and homeostasis. Discectomy and cage insertion were performed through the auxiliary port. Cage level and position were confirmed using the C-arm. The duration of the surgical procedure was recorded. Surgical notes were maintained to record the anatomical structures encountered during the procedure, robotic maneuvers during discectomy and cage insertion, and complications, if any.

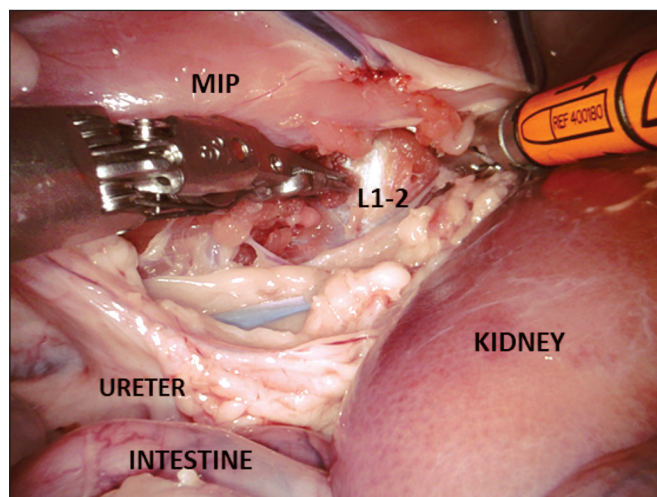
## ■ RESULTS

The 12-mm port for the endoscope camera was inserted using a suitable trocar. The abdomen was then inflated with CO<sub>2</sub> for proper anatomical visualization for the lumbar spinal approach. The 8-mm ports were placed on the left and right sides at least 5 cm from the endoscopic port. These ports were placed under the direction of green laser of the robotic system. The port for the endoscope camera was positioned at the junction of the green guidelines. Later in the process, the robot-assisted system was positioned according to laser instructions. Perforated bipolar forceps on the left robotic arm and curved bipolar forceps on the right robotic arm were inserted intraperitoneally through lateral ports. At this stage, the endoscope was modified to provide an intraperitoneal view. Initially, the intestines were viewed in the intra-abdominal space. Continuous CO<sub>2</sub> inflation enabled spontaneous intestinal retraction, following which the right kidney was observed. The right kidney was separated from the surrounding tissues using the curved bipolar forceps and retracted anteriorly. The iliopsoas muscle was observed following the displacement of the kidney (Figure 1). Then, the lumbar spine and adjacent central vascular structures were identified in the inferomedial aspect of the iliopsoas muscle. Dissection of the iliopsoas muscle revealed the lateral portion of the vertebral corpus and posterior portion of the inferior vena cava. Care was taken to protect the vital organs, ureter, primary vascular structures, and neural plexus during the iliopsoas muscle dissection. The area of interest (disc level) was confirmed using the C-arm, which remained stable throughout the procedure. After confirming the disc level with the C-arm, the muscle and ligament structures around the intervertebral disc were separated via posterior iliopsoas muscle dissection (Figure 2). An assistant surgeon with an endoscopic view of the robot-assisted system performed discectomy via the auxiliary port (12-mm), using a punch and curette, and cage insertion (Figure 3). The level and position of the cage were controlled using the C-arm (Figure 4). At the end of the procedure, all instruments were carefully removed under endoscopic guidance, and the entry points were sutured.

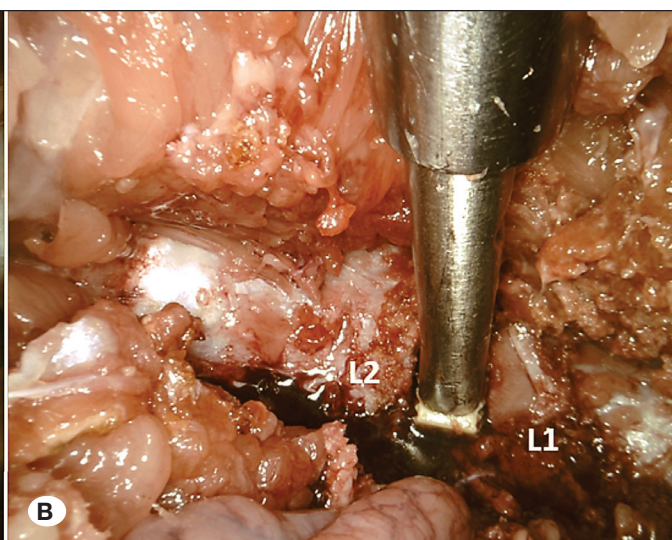
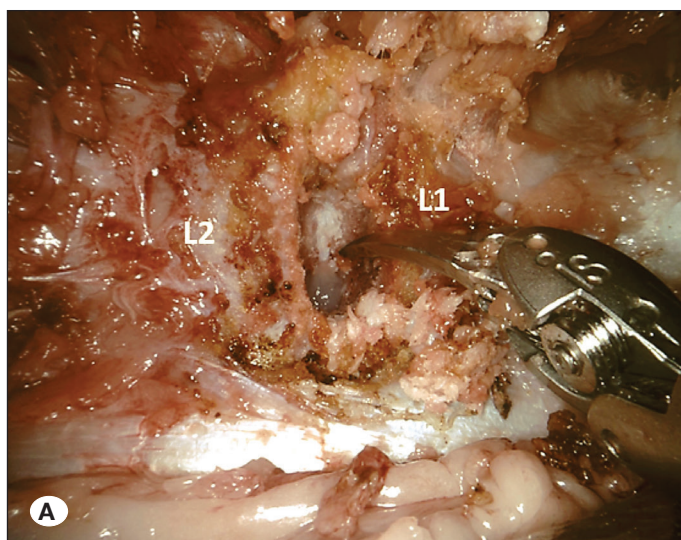
No complications were observed during the procedure. The operative time was 80 min: positioning and preparing the



**Figure 1:** Iliopsoas muscle (MIP) is observed by retracting kidney anteriorly. **RA 1:** Robotic Arm 1 (fenestrated bipolar forceps). **RA 2:** Robotic Arm 2 (curved bipolar dissector).



**Figure 2:** Following the confirmation of the spinal level by the C-arm fluoroscopy, the disc space is exposed by dissection of iliopsoas muscle (MIP) posteriorly. **RA 1:** Robotic Arm 1 (fenestrated bipolar forceps). **RA 2:** Robotic Arm 2 (curved bipolar dissector).



**Figure 3: A, B)** L1-2 discectomy is performed by the robotic instruments. Following total discectomy, the cage is placed by manually via robotic arm.

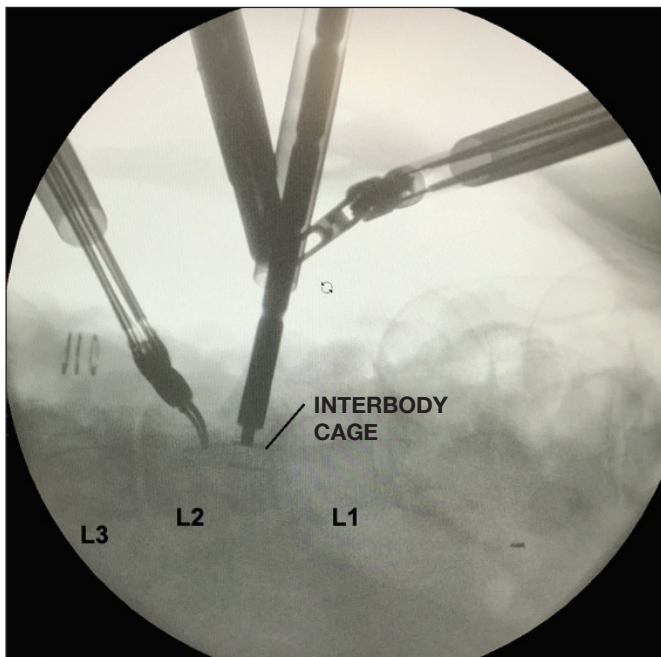
robot-assisted system, 20 min; port placement, connection, and intraperitoneal placement of robotic arms, 15 min; confirmation of the level with C-arm, 20 min; discectomy and cage insertion, 15 min; and control and locking the cage in position with the C-arm, 10 min.

## DISCUSSION

Robot-assisted systems have not received the expected attention in the fields of neurosurgery and spinal surgery, despite their frequent use in urology, cardiothoracic surgery, gynecology, and general surgery (56). Minimally invasive procedures have become more popular for decreasing the complications of spinal surgery. Robot-assisted surgery is a minimally invasive procedure. The Da Vinci Surgical System,

approved by the FDA in 2000, has been used in many surgical fields (12,32,37). The Da Vinci Xi Surgical System consists of four robotic arms and a monitor for the assistant. Each arm consists of a main joint and a link joint that offers ergonomics similar to six-way hand movements. Because of this feature, the robotic system has a mechanical ergonomic advantage over the traditional laparoscopic system (23).

XLIF has been used to prevent vascular injuries observed with anterior lumbar interbody fusion (ALIF) and extra muscular dissection associated with transforaminal lumbar interbody fusion (TLIF), posterior lumbar interbody fusion (PLIF), and posterolateral lumbar fusion (15). In addition, XLIF surgeries have almost one-third shorter operative times and two-thirds lesser intraoperative bleeding amounts than TLIF surgeries



**Figure 4:** The level and position of the cage is confirmed by the C-arm fluoroscopy.

(20). However, anatomical studies have shown that dissection through the iliopsoas muscle puts the lumbar plexus and iliohypogastric, ilioinguinal, lateral femoral cutaneous, genitofemoral, and subcostal nerves at risk of injury (2,18,53). Numerous studies have reported high rates of new sensory (5.15%–75%), new motor (5.15%–40%), and vascular (0.03%–0.04%) injuries following XLIF procedures (15,16,25,30,42,47). Uribe et al. defined safe working zones for minimally invasive XLIF in a cadaveric study (53). All parts of the lumbar plexus, including nerve roots, were found within the psoas muscle posterior to the dorsal fourth of the vertebral body. Safe zones for dissections during minimally invasive XLIF were the middle posterior quarter of the vertebral body from L1-L2 to L3-L4 and midpoint of the vertebral body at the L4-L5 disc space (53). During the transpsoas approach, the subcostal nerve is the dominant nerve observed in the lateral position (2). Complete or partial nerve injuries can occur during the retroperitoneal transpsoas approach when performing blunt retroperitoneal dissection or when using retractor blades (18). In this study, we observed the nerves and vascular structures through an endoscopic view and could safely retract them together with the psoas muscle.

Vascular injury during XLIF surgeries (trauma to the great arteries, segmental arteries, and great vessels leading to retroperitoneal hematoma) has rarely been reported in the literature (13,41,46). Bowel perforation is another important issue in XLIF surgery (14) and has been reported at a range of 0.03%–12.5% in patients receiving XLIF insertion (5,16,21,40,45,48,51,54). Hwang et al. reported an increased risk of bowel perforation when there are more than three levels of operated segments using the lateral retroperitoneal approach or when the procedure is performed specifically

at the L2-L3 and/or L3-L4 levels (21). Bowel perforation is associated with a high mortality (11.1%–79%) and morbidity risk (7,8). An endoscopic view not only prevents nerve injuries but also bowel and vascular injuries. Hence, a robot-assisted approach can be valuable in this sense.

Cage malposition and overhang are co-factors causing pseudoarthrosis because of unsuccessful fusion attempts at the operated levels (11,13,44). Cage insertion zones within the disc space for XLIF are the central (45%), anterior one-third (34%), and posterior one-third (7%) parts. Cage overhang was observed in 45% of cases with cage insertion in the anterior one-third of the disc space (44). In addition to preoperative planning with computed tomography and magnetic resonance imaging, a clear direct intraoperative view increases the success of XLIF surgery for proper cage insertion.

Several studies have reported that surgeons frequently experience discomfort because of non-ergonomic working positions (34,36). Although ergonomic studies on spinal surgeries are lacking, poor ergonomics undoubtedly limits the quality of surgical results. In contrast, surgeons using robot-assisted systems have lower discomfort levels even during day-long operations (43). Robot-assisted systems are likely to improve the quality of spinal surgery by improving the ergonomics of spine surgeons. The surgical console reduces potential unwanted injuries by converting large movements into much smaller precise movements. Tremor filtering and motion scaling functions also contribute to this feature (38). Robot-assisted systems provide better magnification and depth perception than traditional laparoscopic systems with three-dimensional image perception. Two parallel optical systems combined with the right and left eyes allow the three-dimensional image to be projected onto the surgeon's eyes. The adaptation of microscopic specialists, such as neurosurgeons, to this system is more effortless than that of other professionals.

Massive vascular injuries and marked increase in retrograde ejaculation in male patients because of strong traction, cutting, and coagulation of autonomic nerves are significant disadvantages of the laparoscopic anterior approach to the lumbar vertebra (10,22,24). Several studies have reported a low incidence of sexual dysfunction following dissection and nerve-sparing procedures using robotic systems in radical prostatectomy (31,50,52). This technique has been safely and successfully applied to animals and humans for ALIF insertion into the lower lumbar spine (6,28,56). One study used a robotic system for oblique lumbar interbody fusion (OLIF) surgery. However, in this case, the authors used the robotic system for the insertion of transpedicular screws, not the cage itself (55). There have been no reported cases of XLIF cage insertion via robotic systems till date. The endoscopic view of the robotic system made the dissection of the nerves and vascular structures out of view easy. Hence, a safe corridor for dissection and cage insertion can be obtained. In addition, it was easier to accommodate the cage within the disc space. A recent comparative study revealed that lateral approaches at the lower lumbar levels had greater radiation exposure (49). In the present study, we used the C-arm twice: once for

confirmation of the surgical level and once for confirmation of the cage position within the disc space.

To analyze the superiority of these procedures, robot-assisted and conventional laparoscopic surgical procedures should be compared first in cadavers and then in clinical practice.

Robot-assisted systems have advanced significantly over the last two decades. However, they have clear limitations in neurosurgery and spinal surgery. Haptic feedback is important for maintaining important structures intact during operations. The lack of haptic feedback is a significant drawback in robotic systems (33). However, experience and visual attention can overcome this drawback, as shown in other surgical disciplines. A more important limitation of the current Da Vinci Xi Surgical System is that it has no toolkit for managing bone structures. In addition, robotic systems have high start-up, training, and maintenance costs compared with traditional surgical methods (33). Some studies have evaluated the cost-effectiveness of robot-assisted spinal surgery and shown promising results at the 1-year follow-up because of fewer revision surgeries, lower infection rates, reduced operative times, and shortened in-hospital stay (35).

Anatomically, swine and humans exhibit differences. In swine, the disc space is narrower, and the thoracic and lumbar spine have kyphotic curvature (26,43). Therefore, a smaller cage was used in the present study. Lumbar kyphotic curvature causes the spine to remain closer to important structures such as the kidney and intestine during the procedure. Lumbar lordotic curvature in humans would make robot-assisted surgery easier.

Because of the COVID-19 pandemic, there may be limitations and delays in the application of surgical procedures. In addition, doctors, nurses, and other healthcare professionals are at high risk of infection (57). Robot-assisted minimally invasive surgical procedures would shorten the duration of surgeries and of in-hospital stay and decrease bleeding. Thus, the risk of COVID-19 could be reduced with less contact with patients, doctors, and other healthcare workers.

## ■ CONCLUSION

This study showed that robot-assisted surgery for XLIF can be successfully performed and dissection of neurovascular structures can be performed from the operative field with more ease and without harm. Discectomy and proper cage insertion were smoothly performed compared with the conventional open or mini XLIF procedures. Higher costs and maintenance fees are the drawbacks of robot-assisted XLIF surgeries; however, it reduces cost in the long-term as fewer revision surgeries are required. Further cadaveric and clinical studies are warranted to better delineate the superiority of robot-assisted spinal procedures over conventional laparoscopic procedures.

## ■ ACKNOWLEDGEMENTS

The authors would like to express their sincere gratitudes to Prof. Ian SUK (Johns Hopkins University, School of Medicine,

Department of Arts as Applied to Medicine) for his artistic touch to the images of the manuscript, his attention to detail and his availability.

Our dear colleague, our friend Ahmet Akbas, M.D., unfortunately, died at a young age due to COVID-19 infection. We'd like to thank him for his contribution and efforts to the article. This paper is dedicated to the memory of Dr. Ahmet Akbas, M.D.

## ■ AUTHORSHIP CONTRIBUTION

**Study conception and design:** AG, MSE, MBG

**Data collection:** GB, AG, BO

**Analysis and interpretation of results:** GB, AG, MSE

**Draft manuscript preparation:** GB, AG, BO, SA, EA

**Critical revision of the article:** GB, AG, BO

**Other (study supervision, fundings, materials, etc...):** CC, MEA, MSE

All authors (GB, AG, MBG, BO, SA, EA, CC, MEA, MSE) reviewed the results and approved the final version of the manuscript.

## ■ REFERENCES

1. Alluri RK, Avrumova F, Sivaganesan A, Vaishnav AS, Lebl DR, Qureshi SA: Overview of robotic technology in spine surgery. *HSS J* 17:308-316, 2021
2. Alonso F, Graham R, Rustagi T, Drazin D, Loukas M, Oskouian RJ, Chapman JR, Tubbs RS: The subcostal nerve during lateral approaches to the lumbar spine: An anatomical study with relevance for injury avoidance and postoperative complications such as abdominal wall hernia. *World Neurosurgery* 104:669-673, 2017
3. Ballantyne GH: Robotic surgery, telerobotic surgery, telepresence, and telementoring. *Surg Endos* 16:1389-1402, 2002
4. Ballantyne GH, Moll F: The da Vinci telerobotic surgical system: The virtual operative field and telepresence surgery. *Surg Clin North Am* 83:1293-1304, 2003
5. Balsano M, Carlucci S, Ose M, Boriani L: A case report of a rare complication of bowel perforation in extreme lateral interbody fusion. *Eur Spine J* 24:405-408, 2015
6. Beutler WJ, Peppelman WC, DiMarco LA: The da Vinci robotic surgical assisted anterior lumbar interbody fusion: Technical development and case report. *Spine* 38:356-363, 2013
7. Bielecki K, Kamiński P, Klukowski M: Large bowel perforation: Morbidity and mortality. *Tech Coloproctol* 6:177-182, 2002
8. Biondo S, Parés D, Martí Ragué J, De Oca J, Toral D, Borobia FG, Jaurieta E: Emergency operations for nondiverticular perforation of the left colon. *Am J Surg* 183:256-260, 2002
9. Cadière GB, Himpens J, Gernay O, Izizaw R, Degueudre M, Vandromme J, Capelluto E, Bruyns J: Feasibility of robotic laparoscopic surgery: 146 cases. *World J Surg* 25:1467-1477, 2001

10. Chung SK, Lee SH, Lim SR, Kim DY, Jang JS, Nam KS, Lee HY: Comparative study of laparoscopic L5/S1 fusion versus open mini-ALIF, with a minimum 2-year follow-up. *Eur Spine J* 12:613-617, 2003
11. Daffner SD, Wang JC: Migrated XLIF cage: Case report and discussion of surgical technique. *Orthopedics* 33(7):518, 2010
12. Davies B: A review of robotics in surgery. *Proc Inst Mech Eng H* 214:129-140, 2000
13. Epstein NE: Non-neurological major complications of extreme lateral and related lumbar interbody fusion techniques. *Surg Neurol Int* 7 Suppl 25:S656-S659, 2016
14. Epstein NE: Perspective on the true incidence of bowel perforations occurring with extreme lateral lumbar interbody fusions. How should they be treated? *Surg Neurol Int* 12:576, 2021
15. Epstein NE: Review of risks and complications of extreme lateral interbody fusion (XLIF). *Surg Neurol Int* 10:237, 2019
16. Fujibayashi S, Kawakami N, Asazuma T, Ito M, Mizutani J, Nagashima H, Nakamura M, Sairyo K, Takemasa R, Iwasaki M: Complications associated with lateral interbody fusion: Nationwide survey of 2998 cases during the first 2 years of its use in Japan. *Spine* 42:1478-1484, 2017
17. Goh KY, Hsu JC, Lee CY, Huang TJ, Chen CM, Wu MH: Uniportal endoscopic interlaminar decompression in lumbar spinal stenosis: A comprehensive review. *Int J Spine Surg* 15: S54-S64, 2021
18. Grunert P, Drazin D, Iwanaga J, Schmidt C, Alonso F, Moisi M, Chapman JR, Oskouian RJ, Tubbs RS: Injury to the lumbar plexus and its branches after lateral fusion procedures: A cadaver study. *World Neurosurg* 105:519-525, 2017
19. Gungor A, Berikol G, Berke Goztepe M, Ozoner B, Eksi MS: Thoracic vertebra interbody fusion surgery with robotic assisted system in a swine model. *J Clin Neurosci* 92:85-88, 2021
20. Hiyama A, Katoh H, Sakai D, Tanaka M, Sato M, Watanabe M: Short-term comparison of preoperative and postoperative pain after indirect decompression surgery and direct decompression surgery in patients with degenerative spondylolisthesis. *Sci Rep* 10:18887, 2020
21. Hwang ES, Kim KJ, Lee CS, Lee MY, Yoon SJ, Park JW, Cho JH, Lee DH: Bowel injury and insidious pneumoperitoneum after lateral lumbar interbody fusion. *Asian Spine J* 2021 (Online ahead of print)
22. Inamasu J, Guiot BH: Laparoscopic anterior lumbar interbody fusion: A review of outcome studies. *Minim Invasive Neurosurg* 48:340-347, 2005
23. Jiménez-Rodríguez RM, Rubio-Dorado-Manzanares M, Díaz-Pavón JM, Reyes-Díaz ML, Vazquez-Monchul JM, Garcia-Cabrera AM, Padillo J, De la Portilla F: Learning curve in robotic rectal cancer surgery: Current state of affairs. *Int J Colorectal Dis* 31:1807-1815, 2016
24. Kaiser MG, Haid RW, Subach BR, Miller JS, Smith CD, Rodts GE: Comparison of the mini-open versus laparoscopic approach for anterior lumbar interbody fusion: A retrospective review. *Neurosurgery* 51:97-103; discussion 103-105, 2002
25. Khajavi K, Shen A, Lagina M, Hutchison A: Comparison of clinical outcomes following minimally invasive lateral interbody fusion stratified by preoperative diagnosis. *Eur Spine J* 24: 322-330, 2015
26. Kim MJ, Ha Y, Yang MS, Yoon DH, Kim KN, Kim H, Yang JW, Lee JYK, Yi S, Jung WJ, Rha KH: Robot-assisted anterior lumbar interbody fusion (ALIF) using retroperitoneal approach. *Acta Neurochir* 152:675-679, 2010
27. Lanfranco AR, Castellanos AE, Desai JP, Meyers WC: Robotic surgery: A current perspective. *Ann Surg* 239:14-21, 2004
28. Lee DS, Park KS, Park MS: The comparative analysis of clinical characteristics and surgical results between the upper and lower lumbar disc herniations. *J Korean Neurosurg Soc* 54:379-383, 2013
29. Lee JYK, O'Malley BW, Newman JG, Weinstein GS, Lega B, Diaz J, Grady MS: Transoral robotic surgery of craniocervical junction and atlantoaxial spine: A cadaveric study: Laboratory investigation. *SPI* 12:13-18, 2010
30. Li J, Wang X, Sun Y, Zhang F, Gao Y, Li Z, Ding W, Shen Y, Zhang W: Safety analysis of two anterior lateral lumbar interbody fusions at the initial stage of learning curve. *World Neurosurgery* 127:e901-e909, 2019
31. Ljunggren C, Ströberg P: Improvement in sexual function after robot-assisted radical prostatectomy: A rehabilitation program with involvement of a clinical sexologist. *Cent European J Urol* 68(2):214-220, 2015
32. Mack MJ: Minimally invasive and robotic surgery. *JAMA* 285: 568, 2001
33. Marcus HJ, Hughes-Hallett A, Cundy TP, Yang GZ, Darzi A, Nandi D: da Vinci robot-assisted keyhole neurosurgery: A cadaver study on feasibility and safety. *Neurosurg Rev* 38:367-371, 2015
34. Matern U, Konecny S: Safety, hazards and ergonomics in the operating room. *Surg Endosc* 21:1965-1969, 2007
35. Menger RP, Savardekar AR, Farokhi F, Sin A: A cost-effectiveness analysis of the integration of robotic spine technology in spine surgery. *Neurospine* 15:216-224, 2018
36. Mirbod SM, Yoshida H, Miyamoto K, Miyashita K, Inaba R, Iwata H: Subjective complaints in orthopedists and general surgeons. *Int Arch Occup Environ Health* 67:179-186, 1995
37. Moorthy K, Munz Y, Dosis A, Hernandez J, Martin S, Bello F, Rockall T, Darzi A: Dexterity enhancement with robotic surgery. *Surg Endosc* 18(5):790-795, 2004
38. Nathoo N, Cavusoglu MC, Vogelbaum MA, Barnett GH: In touch with robotics: Neurosurgery for the future. *Neurosurgery* 56:421-433, 2005
39. Passerotti C, Peters CA: Robotic-assisted laparoscopy applied to reconstructive surgeries in children. *World J Urol* 24:193-197, 2006
40. Paterakis KN, Brotis AG, Paschalis A, Tzannis A, Fountas KN: Extreme lateral lumbar interbody fusion (XLIF) in the management of degenerative scoliosis: A retrospective case series. *J Spine Surg* 4:610-615, 2018

41. Peiró-García A, Domínguez-Esteban I, Alía-Benítez J: Retroperitoneal haematoma after using the extreme lateral interbody fusion (XLIF) approach: Presentation of a case and a review of the literature. *Rev Esp Cir Ortop Traumatol* 60:330-334, 2016
42. Pereira EAC, Farwana M, Lam KS: Extreme lateral interbody fusion relieves symptoms of spinal stenosis and low-grade spondylolisthesis by indirect decompression in complex patients. *J Clin Neurosci* 35:56-61, 2017
43. Ponnusamy K, Cheung S, Mohr C: Robotic approaches to the posterior spine. *Spine* 34:2104-2109, 2009
44. Regev GJ, Haloman S, Chen L, Dhawan M, Lee YP, Garfin SR, Kim CW: Incidence and prevention of intervertebral cage overhang with minimally invasive lateral approach fusions. *Spine* 35:1406-1411, 2010
45. Rustagi T, Yilmaz E, Alonso F, Schmidt C, Oskouian R, Tubbs RS, Chapman JR, Hopkins S, Schildhauer TA, Fisahn C: Iatrogenic bowel injury following minimally invasive lateral approach to the lumbar spine: A retrospective analysis of 3 cases. *Global Spine J* 9:375-382, 2019
46. Santillan A, Patsalides A, Gobin YP: Endovascular embolization of iatrogenic lumbar artery pseudoaneurysm following extreme lateral interbody fusion (XLIF). *Vasc Endovascular Surg* 44:601-603, 2010
47. Segawa T, Inanami H, Koga H: Clinical evaluation of microendoscopy-assisted extreme lateral interbody fusion. *J Spine Surg* 3:398-402, 2017
48. Siasios I, Vakharia K, Khan A, Meyers JE, Yavorek S, Pollina J, Dimopoulos V: Bowel injury in lumbar spine surgery: A review of the literature. *J Spine Surg* 4:130-137, 2018
49. Striano BM, Xiong GX, Lightsey HM, Crawford AM, Pisano AJ, Schoenfeld AJ, Simpson AK: Comparison of radiation exposure between anterior, lateral, and posterior interbody fusion techniques and the influence of patient and procedural factors. *Spine* 46:1669-1675, 2021
50. Tewari A, Rao S, Martinez-Salamanca JI, Leung R, Ramanathan R, Mandhani A, Vaughan ED, Menon M, Horninger W, Tu J, Bartsch G: Cancer control and the preservation of neurovascular tissue: How to meet competing goals during robotic radical prostatectomy. *BJU Int* 101:1013-1018, 2008
51. Tormenti MJ, Maserati MB, Bonfield CM, Okonkwo DO, Kanter AS: Complications and radiographic correction in adult scoliosis following combined transpsoas extreme lateral interbody fusion and posterior pedicle screw instrumentation. *Neurosurg Focus* 28(3):E7, 2010
52. Tsikis ST, Nottingham CU, Faris SF: The relationship between incontinence and erectile dysfunction after robotic prostatectomy: Are they mutually exclusive? *J Sex Med* 14:1241-1247, 2017
53. Uribe JS, Arredondo N, Dakwar E, Vale FL: Defining the safe working zones using the minimally invasive lateral retroperitoneal transpsoas approach: An anatomical study: Laboratory investigation. *J Neurosurg Spine* 13:260-266, 2010
54. Uribe JS, Deukmedjian AR: Visceral, vascular, and wound complications following over 13,000 lateral interbody fusions: A survey study and literature review. *Eur Spine J* 24:386-396, 2015
55. Wu J, Yuan Q, Liu Y, Sun Y, Zhang Y, Tian W: Robot-assisted percutaneous transfacet screw fixation supplementing oblique lateral interbody fusion procedure: Accuracy and safety evaluation of this novel minimally invasive technique. *Orthop Surg* 11:25-33, 2019
56. Yang MS, Yoon DH, Kim KN, Kim H, Yang JW, Yi S, Lee JYK, Jung WJ, Rha KH, Ha Y: Robot-assisted anterior lumbar interbody fusion in a swine model in vivo test of the Da Vinci surgical-assisted spinal surgery system. *Spine* 36:E139-E143, 2011
57. Zhou P, Yang XL, Wang XG, Hu B, Zhang L, Zhang W, Si HR, Zhu Y, Li B, Huang CL, Chen HD, Chen J, Luo Y, Guo H, Jiang RD, Liu MQ, Chen Y, Shen XR, Wang X, Zheng XS, Zhao K, Chen QJ, Deng F, Liu LL, Yan B, Zhan FX, Wang YY, Xiao GF, Shi ZL: A pneumonia outbreak associated with a new coronavirus of probable bat origin. *Nature* 579:270-273, 2020